

# Diagnosis of Pemphigus vulgaris with Immunoperoxidase staining for IgG and C<sub>3</sub>

N, Ratnatunga<sup>1</sup>, S. Ramadasa<sup>1</sup> and Y. Doolwela<sup>1</sup>

*The Ceylon Journal of Medical Science* 1992; 35: 11-13

## Summary

Demonstration of bound IgG and C<sub>3</sub> around keratinocytes, in the intercellular substance of the epidermis, in the skin lesions of pemphigus vulgaris, is possible using formalin fixed, routinely processed paraffin sections. It is a reliable and sensitive method for use in Sri Lankan laboratories.

**Key words:** Pemphigus vulgaris, IgG, C<sub>3</sub>, immunoperoxidase staining.

## Introduction

Pemphigus vulgaris is a primarily blistering disorder with an autoimmune component. Circulating antibodies to the intercellular substance of the squamous epithelium is seen in this disease (1). Bound immunoglobulins, and complement components can be found in the lesional, perilesional and unaffected epidermis of these patients. The characteristic histology is acantholysis of the supra basal region of the epidermis. However, in certain circumstances other entities such as Darrier's disease, benign familial pemphigus, impetigo, dermatitic and drug reactions have to be distinguished from Pemphigus vulgaris. Demonstration of bound IgG and C<sub>3</sub> in the epidermal intercellular substance, then becomes important for the diagnosis of Pemphigus vulgaris. The routine mode of demonstration is by the direct immunofluorescent technique. However due to necessity of a cryostat and freezing material, the immunofluorescent technique is not a very practical method for Sri Lankan laboratories. On the other hand immunoperoxidase staining procedures are more feasible, as sophisticated equipment is not required. To the best of our knowledge there is no published data regarding immunoperoxidase staining of skin biopsies in Sri Lanka.

The aim of this study was to find out whether an immunoperoxidase stain could be applied on

routinely fixed and processed paraffin sections for the demonstration of bound IgG and C<sub>3</sub> in the skin tissue of patients with Pemphigus vulgaris.

## Materials and Method

Skin biopsies were utilised – as follows:

Pemphigus vulgaris – lesional and perilesional skin – 6 cases.

Subepidermal bullous disorders – lesional and perilesional skin – 4 cases.

Non bullous skin disorders – 2 cases.

Both lesional and perilesional skin were included in the biopsies.

All biopsies were fixed in non buffered formalin for over 24 hours.

Paraffin sections were cut at 4-6 microns, and mounted on slides coated with poly-L-lysine. Two parallel sets of slides were used.

Sections were brought to water and washed in distilled water warmed to 37°C.

One set of cases were digested with 0.05% protease XXIV in Tris/HCl (pH 7.5) for 7 minutes at 37°C. The other was not subject to digestion.

After stopping digestion by immersing the relevant slides in cold Tris/HCl (pH 7.5) for 30 minutes, sections were next stained by the 3 stage strept-avidin biotin staining procedure, as described in the literature circulated by DAKO.

The buffer used was phosphate buffered saline (PBS) at pH 7.2. Blocking of endogenous peroxidase activity was not carried out, as previous studies revealed that this did not cause a problem of non-specific staining. The procedure was as follows, in brief:

After the digestion procedure, the sections were washed in cold PBS. All sections were pre-treated with 1/10 normal swine serum.

1st stage – DAKO polyclonal rabbit antibodies to IgG, (A423) 1/200 – 1/350, and polyclonal

<sup>1</sup> Department of Pathology, Faculty of Medicine, University of Peradeniya.

rabbit antibodies to C<sub>3</sub>, (A062) 1/100 – 1/200. – 30 minutes.

2nd stage – DAKO biotinylated swine anti-rabbit (E 353) – 1/300. – 30 minutes.

3rd stage – DAKO strept-avidin biotin peroxidase (K377) complex. 30 minutes.

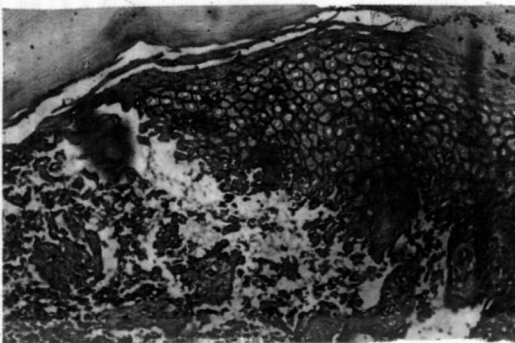
The peroxidase label was demonstrated with the chromogen 3, 3'-diaminobenzidine tetrahydrochloride (DAB) at a concentration of 0.5 mg/ml Tris PBS (pH 7.6) with added 1% hydrogen peroxide per ml of DAB.

The sections were washed in phosphate buffered saline (pH 7.2) after each stage, except after the application of swine serum.

The nuclei were stained with Carazzi's Haematoxylin, and the sections were dehydrated and mounted in DPX, and examined with a light microscope.

### Results

Good results were obtained only after protease digestion. Clear staining for IgG was seen around the keratinocytes in the roof of the bulla, and perilesional epidermis, Figs. 1 & 2. The staining intensity was greater in the supra basal region, Fig. 1.

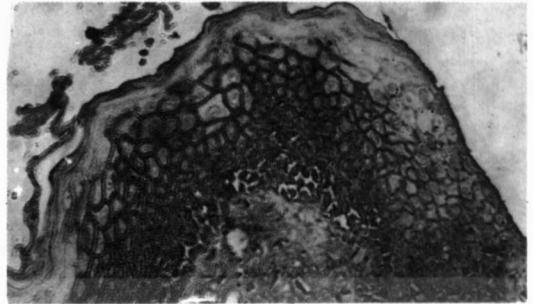


**Fig. 1**

Dark staining for IgG around keratinocytes. Immunoperoxidase, 6 x 10.

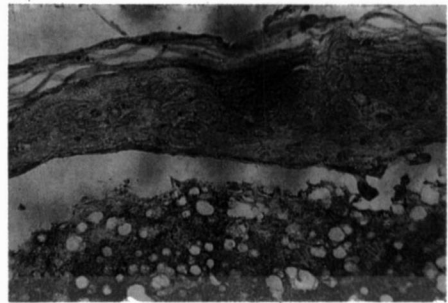
The control slides showed no staining, Figs. 3 & 4.

Staining for C<sub>3</sub> showed a similar pattern, Fig. 5.



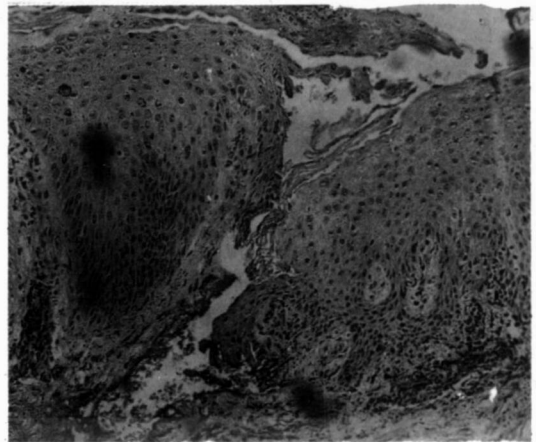
**Fig. 2**

Staining for IgG in the perilesional epidermis mostly in the supra basal region. Immunoperoxidase, 6 x 20.



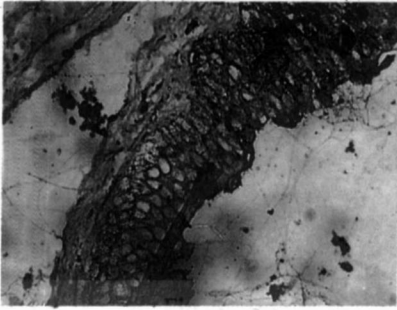
**Fig. 3**

Sub-epidermal bulla. Skin showing no staining. 6 x 20.



**Fig. 4**

Normal skin showing no staining. 6 x 10.



**Fig. 5**

Positive staining for C<sub>3</sub> around keratinocytes in the roof of the bulla. 6 x 20.

#### **Discussion and Conclusion**

In Pemphigus vulgaris, the antibodies deposited in the intercellular substance of the epidermis,

belong to the IgG class. IgA, M and C<sub>3</sub> deposition also occurs. The common method of demonstrating these bound antibodies is by direct immunofluorescent testing. The immunoperoxidase technique, described in this paper, is a sensitive and practicable method for use in Sri Lankan laboratories. It also affords the facility of specimens being received in a central laboratory from other parts of the Island, as these can be transported in formalin, which is readily available in the country.

#### **References**

1. Fleming K. A. *Oxford Textbook of Pathology* Vol 2b. 1st Edition. Oxford University Press, 1992; pp. 2153 - 2185.